Banff concurrent session: Heart

Does chronic antibody-mediated rejection exist in cardiac transplantation?

Patrick Bruneval
Dpt Pathology. G Pompidou hospital. Paris
Paris Transplant Group: http://www.paristransplantgroup.org/en/index.html

Chronic rejection in cardiac transplantation

- **The term of "chronic rejection" is extensively acknowledged in the literature dealing with cardiac transplantation**
- **In both clinical and experimental Tx**
- **[Noninvasive monitoring of acute and chronic rejection in heart transplantation. Crespo-Leiro *et al.* Curr Opin Cardiol *in press*]**
- **[Acute and chronic rejection: Compartmentalization and Kinetics of Counterbalancing Signals in Cardiac Transplants Kaul *et al.* Am J Transplant 2015],**

Chronic rejection

- The term of chronic rejection can be confounding since it sometimes refers only to dysfunction of the solid organ grafts regardless of the mechanisms and the structural changes
- Functional deterioration of grafts is a common denominator from many causes (immune and non-immune): one of the most complex situation being CLAD: chronic lung allograft dysfunction

Chronic rejection in cardiac transplantation

- But most frequently “chronic rejection” in cardiac transplantation refers to cardiac allograft vasculopathy
- The mechanisms of CAV are complex involving immune (true chronic rejection) and non-immune factors →
- Is CAV synonym for chronic rejection?
- Is CAV the unique marker of cardiac chronic rejection?

Chronic rejection in cardiac transplantation

- Therefore the lesions of cardiac chronic rejection have to be determined
- With the goal to characterize markers of chronic rejection

Chronic ABMR in cardiac transplantation

What can we learn from other SOT?

Chronic ABMR in kidney transplantation

- Banff classification recognizes 2 categories of chronic rejection:
  - One mediated by antibodies: “chronic active ABMR”
  - One mediated by T lymphocytes: “chronic active TCMR”

[Loupy *et al.* The Banff 2015 kidney meeting report… Am J Transplant 2017]

Chronic ABMR in kidney transplantation

- **Chronic active ABMR (Banff 2015 kidney meeting report)**

Chronic active ABMR[2]	All three features must be present for diagnosis. As with acute/active ABMR, biopsies showing histological features plus evidence of current/recent antibody interaction with vascular endothelium or DSA, but not both, may be designated as suspicious, and it should be noted if the lesion is C4d-positive or C4d-negative, based on the criteria listed: 1 Histologic evidence of chronic tissue injury, including one or more of the following: • TG (cg >0), if no evidence of chronic thrombotic microangiopathy; includes changes evident by EM only (cg1a; Table 4) • Severe peritubular capillary basement membrane multilayering (requires EM)[3] • Arterial intimal fibrosis of new onset, excluding other causes; leukocytes within the sclerotic intima favor chronic ABMR if there is no prior history of biopsy-proven TCMR with arterial involvement but are not required 2 Evidence of current/recent antibody interaction with vascular endothelium, including at least one of the following: • Linear C4d staining in peritubular capillaries (C4d2 or C4d3 by IF on frozen sections, or C4d >0 by IHC on paraffin sections) • At least moderate microvascular inflammation ([g + ptc] ≥2), although in the presence of acute TCMR, borderline infiltrate, or infection, ptc ≥2 alone is not sufficient and g must be ≥1 • Increased expression of gene transcripts in the biopsy tissue indicative of endothelial injury, if thoroughly validated 3 Serologic evidence of DSAs (HLA or other antigens): • Biopsies suspicious for ABMR on the basis of meeting criteria 1 and 2 should prompt expedited DSA testing

TG, double contours

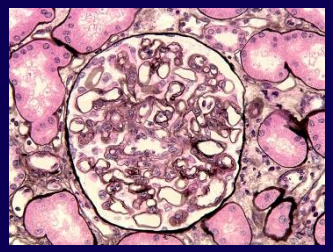

(courtesy of M Rabant)

PTC BM multilayering

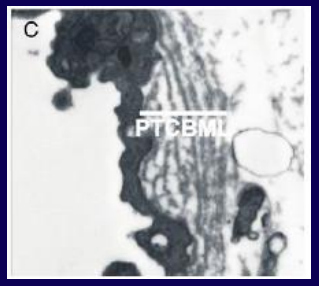

De Kort et al. Transplantation 2016

Arterial intimal fibrosis

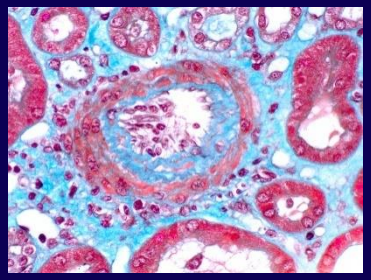

C4d deposits

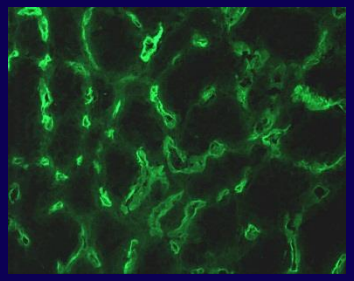

Microvascular inflammation

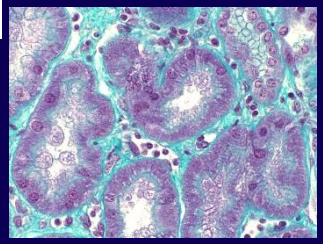

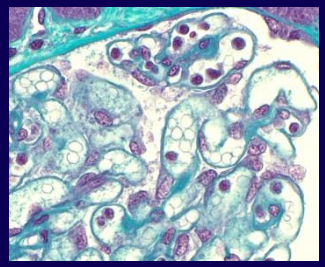

Chronic ABMR in kidney transplantation

In summary at biopsy histology, chronic active ABMR in kidney grafts is:

- **Chronic tissue injury involving:**
  - **The microcirculation (glomerular and/or interstitial)**
  - **The macrocirculation: in arteries, intimal thickening (both in ABMR and TCMR)**
- **Active phenomenon:**
  - **C4d deposits**
  - **Microvascular inflammation (intravascular cells; glomerulitis and peritubular capillaritis with [g + ptc] score ≥2)**
  - **Arteritis: + mononuclear cell inflammation in intimal thickening**

Chronic rejection in other SOT

Liver:

New entity recently published "chronic ABMR in liver allografts" [O'Leary *et al.* Am J transplant 2016]: complex score showing more inflammation and fibrosis (and ± C4d) in DSA-positive patients

Lobular Inflammation
Interface Activity
Portal Tract Collagenization
Portal Venopathy
Sinusoidal Fibrosis

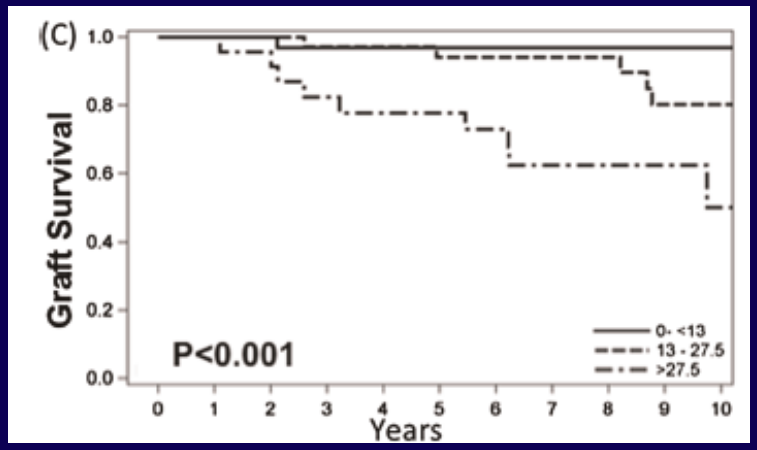

Chronic rejection in other SOT:

<u>Lung</u>: chronic rejection acknowledged in the working formulation of ISHLT nomenclature in the diagnosis of lung rejection including items C and D:

- C: Chronic airway rejection: obliterative bronchiolitis
- D: Chronic vascular rejection: accelerated graft vascular sclerosis

The histopathology task force again recognized that alloreactive injury to the donor can affect both the vasculature and the airways in acute and chronic rejection. [redacted]

[Stewart *et al.* JHLT 2007]

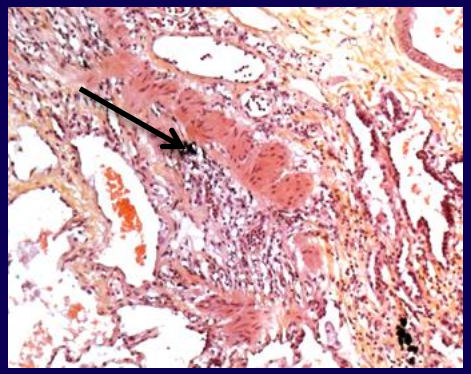

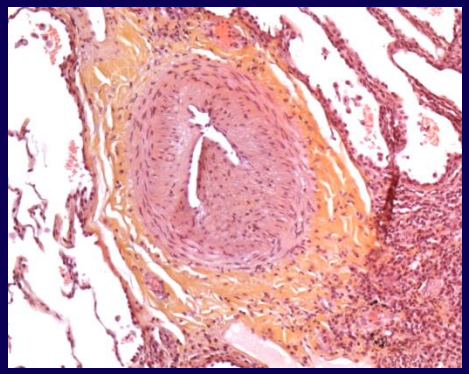

Chronic rejection in other SOT:

<u>Lung</u>: increasing evidence for a role of chronic ABMR in chronic lung rejection *i.e.* obliterative bronchiolitis

Although Banff study on ABMR did not use the name of chronic rejection [Wallace *et al;* JHLT 2016]
Chronic ABMR has been acknowledged in ISHLT consensus document [Levine *et al;* JHLT 2016]

[redacted] Importantly, DSA have also been associated with chronic allograft rejection, as manifested by transplant glomerulopathy in kidney recipients, cardiac allograft vasculopathy in heart recipients and obliterative bronchiolitis (OB) in lung transplant recipients.[3,8,15,16]

[redacted] The group discussed the arbitrary nature of temporal divisions of AMR into hyperacute (occurring intraoperatively or within 24 hours of surgery), acute (often mimicking ACR) and chronic (potentially manifesting as an occult cause of CLAD). Group sentiment was that the important concept of chronic AMR deserves a separate in-depth evaluation as there was insufficient evidence at the time to evaluate causal links between persistent AMR and CLAD, irrespective of how appealing this hypothesis may be.

Chronic ABMR in cardiac transplantation

1. Is the term “chronic ABMR” useful?

2. What is the spectrum of lesions to include in this setting?

1- Is the term of chronic ABMR useful in cardiac transplantation?

To understand the natural history/pathophysiology of cardiac graft failure ~ CAV which is based on:

- **Recurrent episodes of cellular rejection: most of the studies found a relationship between episodes of ACR and CAV [for review: Fredigo *et al.* Cardiac allograft vasculopathy, pp279-305, in The pathology of cardiac transplantation, Springer 2017]**

- **ABMR: Currently it is the main culprit in a background of low incidence of ACR and better diagnosis of ABMR [Wu *et al.* JHLT 2009; Kfoury *et al.* JHLT 2012; Frank *et al.* Am J Clin Pathol 2014; Loupy *et al.* Am J Transplant 2015; Coutance *et al.* JHLT 2015]**

Chronic ABMR in cardiac transplantation

- **For many years experimental pathology confirmed that on-going ACR and ABMR can induce CAV**
- **[Adams *et al.* Chronic rejection in experimental cardiac transplantation: studies in the Lewis-F344 model. Immunol Rev 1993]**
- **[Russell PS *et al.* Coronary atherosclerosis in transplanted mouse hearts. II. Importance of humoral immunity. J Immunol. 1994]**

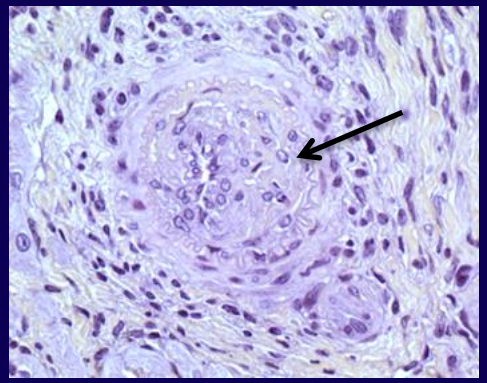

Model of cardiac ABMR in mice treated for 30 d with repeated injections of anti-HB13 antibody (anti-mouse MHC Class I H-2K^k and H-2D^k) showing pathological figures of both acute and chronic ABMR [with O Thaunat, INSERM U1111, Lyon]

Chronic ABMR in cardiac transplantation

The term "chronic" refers to "late" but does not clearly distinguish recurrent, on-going, or fluctuating phenomena

- **ABMR frequently presents as a fluctuating phenomenon with**
  - **Fluctuating DSA**
  - **Fluctuating pathology (pAMR)**
  - **Both being poorly correlated [Clerkin *et al.* JHLT *in press*]**

Chronic ABMR in cardiac transplantation

Fluctuating pathology (pAMR) during the follow-up biopsies in 19 Pts from a series of 40 failing grafts with reTx



[Loupy *et al.* AJT 2016]

Chronic ABMR in cardiac transplantation

The term "chronic ABMR" should clarify if it is an active phenomenon:

- **Microvascular inflammation, IAMC, intravascular CD68-positive cells?**
- **Inflammatory arteriopathy? Not easy to reach on EMB (contrary to kidney biopsy)**

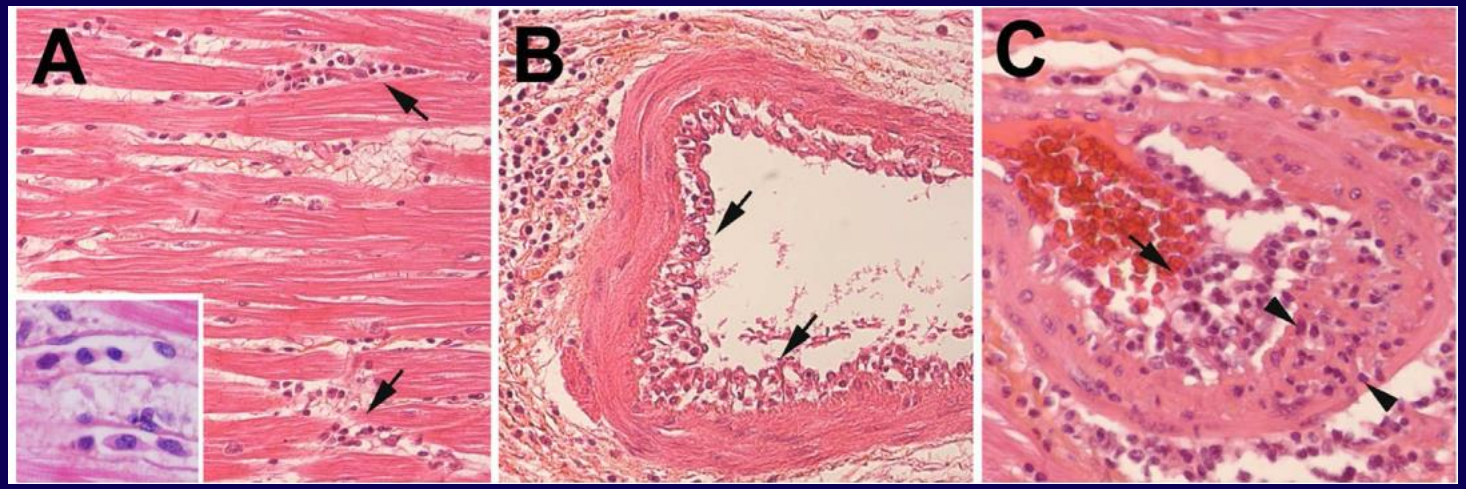

Vascular inflammation in explanted cardiac allografts [Loupy *et al.* AJT 2015]

Chronic ABMR in cardiac transplantation

The term "chronic ABMR" should clarify if it is an active phenomenon:

- **Interaction DSA/cardiac tissue: C4d? or other marker?**
- **Increased transcripts of interest? (endothelial activation transcripts, interferon γ, and NK transcripts associated with CAV: Loupy *et al.* Circulation *in press*)**

Activity would be an argument for immune mechanisms in CAV *vs.* non-immune factors

Chronic ABMR in cardiac transplantation

In summary: to have usefulness the term cABMR should precise that tissue damage occurs as

- an on-going, recurrent, or fluctuating phenomenon
- an active phenomenon

2- The spectrum of lesions to include in cardiac ABMR: CAV

Cardiac allograft vasculopathy is assimilated into chronic rejection.

However:

- **Non-immune factors contribute to the development of CAV**
- **CAV shows a "multifaceted" pathology [Lu *et al.* JHLT 2011] encompassing atherosclerosis, arteriosclerosis, arterial inflammation, fibrosis.**

The spectrum of lesions to include in cardiac chronic ABMR

The question being: are all these lesion patterns reflecting true chronic rejection, particularly atherosclerosis which can be transmitted by the donor heart?

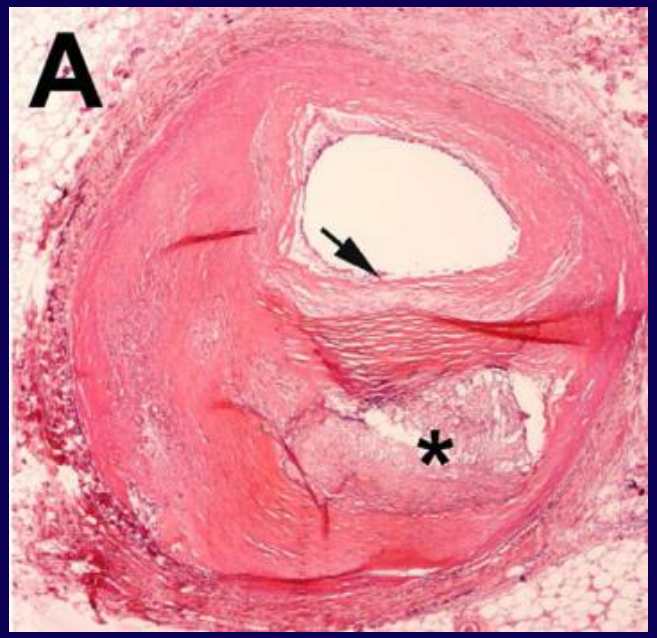

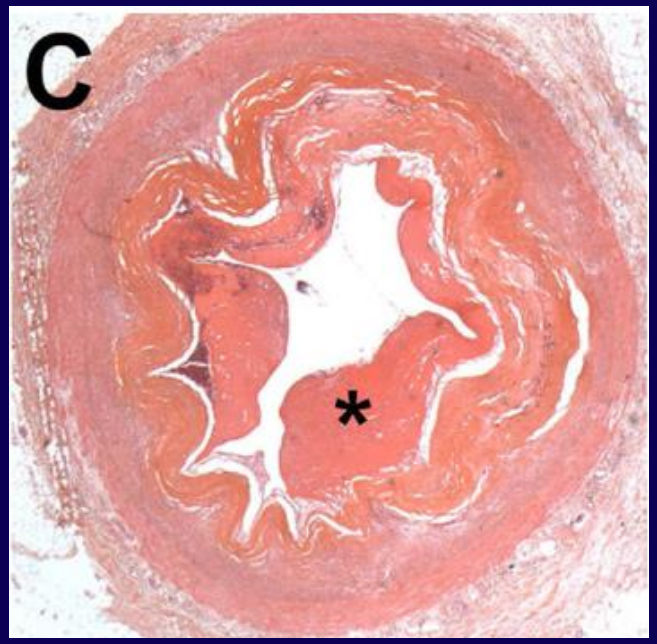

The spectrum of lesions to include in cardiac chronic ABMR

At least atherosclerosis in intramyocardial coronary arteries represents a post-transplant condition (immune?)

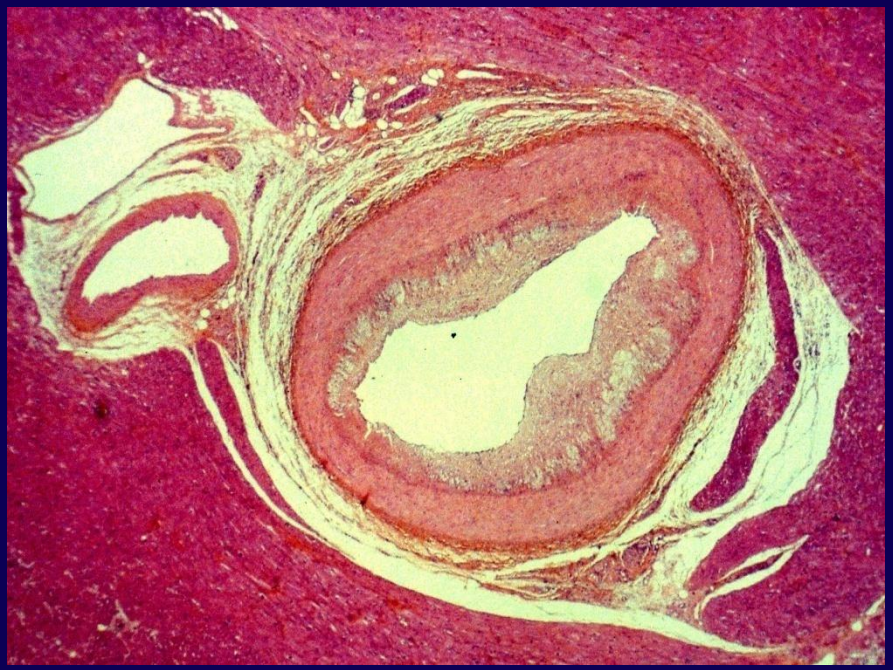

The spectrum of lesions to include in cardiac chronic ABMR

“Immune” arteriosclerosis (intimal hyperplasia, loss of SMC in the media, inflammation) in large and medium-sized artery represents the paradigm of CAV and chronic rejection

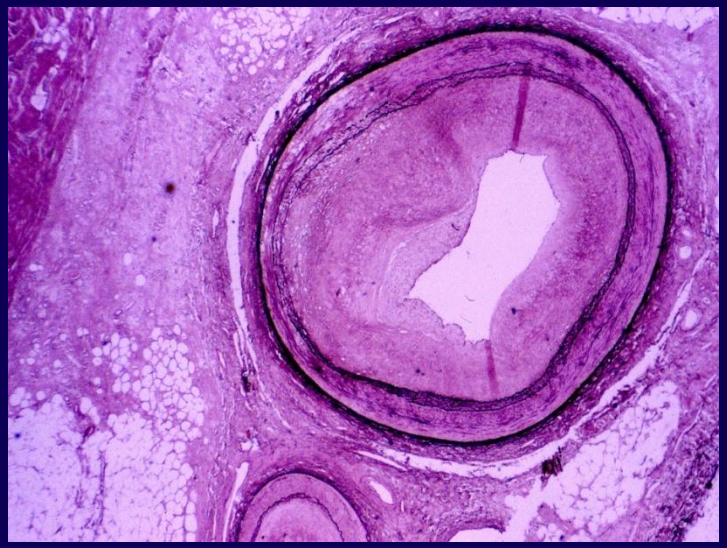

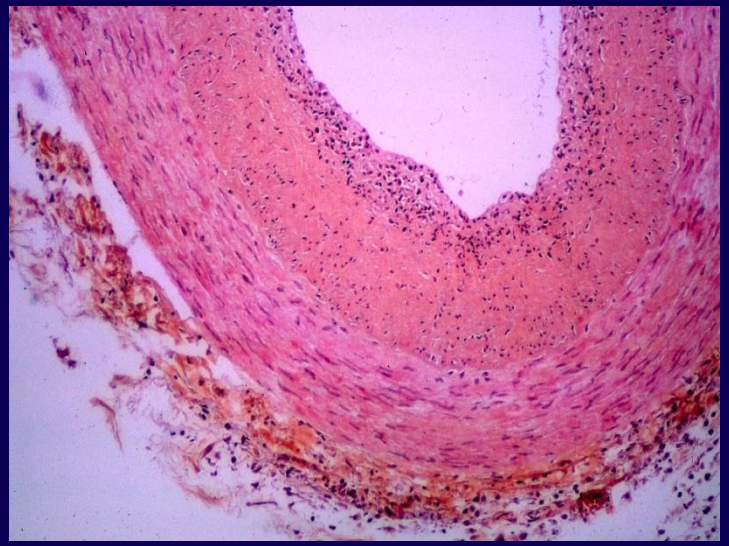

The spectrum of lesions to include in cardiac chronic ABMR: microcirculation

The involvement of the microcirculation in chronic ABMR should be investigated since

- **It is accessible on EMB**
- **Reduced coronary flow reserve is associated with in chronic rejection, namely new onset of CAV [Tona *et al.* Am J Transplant 2015]; Endothelial dysfunction and increased microcirculatory resistances are associated with increased plaque volume at 1 y. post-Tx [Lee *et al.* Circulation 2017]**
- **Structural changes have been described in the microcirculation of EMB**

Structural changes in the microcirculation of EMB

Accumulation of intravascular activated mononuclear cells: the paradigm of ABMR, microcirculation inflammation

- in “acute” = early ABMR
- In late, fluctuating = “chronic” ABMR

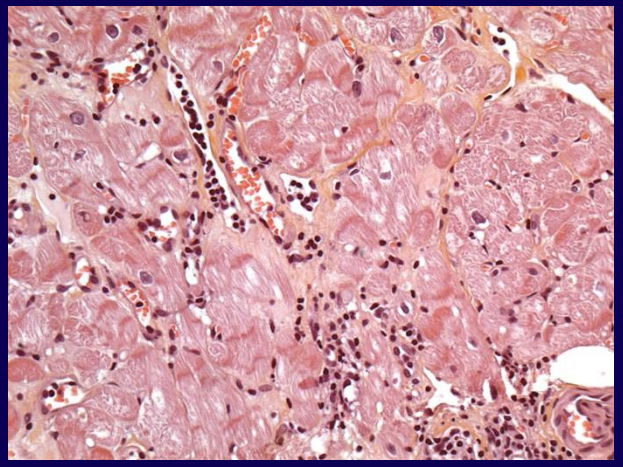

Structural changes in the microcirculation of EMB



Multilaminated basement membrane of perimyocytic capillaries (courtesy of D Miller)

Structural changes in the microcirculation of EMB

Decreased density of microvessels in late (mean 6.52 years) EMB from patients with ABMR and late fatal issue [Revelo *et al.* Cardiovascular Pathol 2012]. Not observed in ABMR still alive patients and in non-rejecting patients. No insight into association with CAV

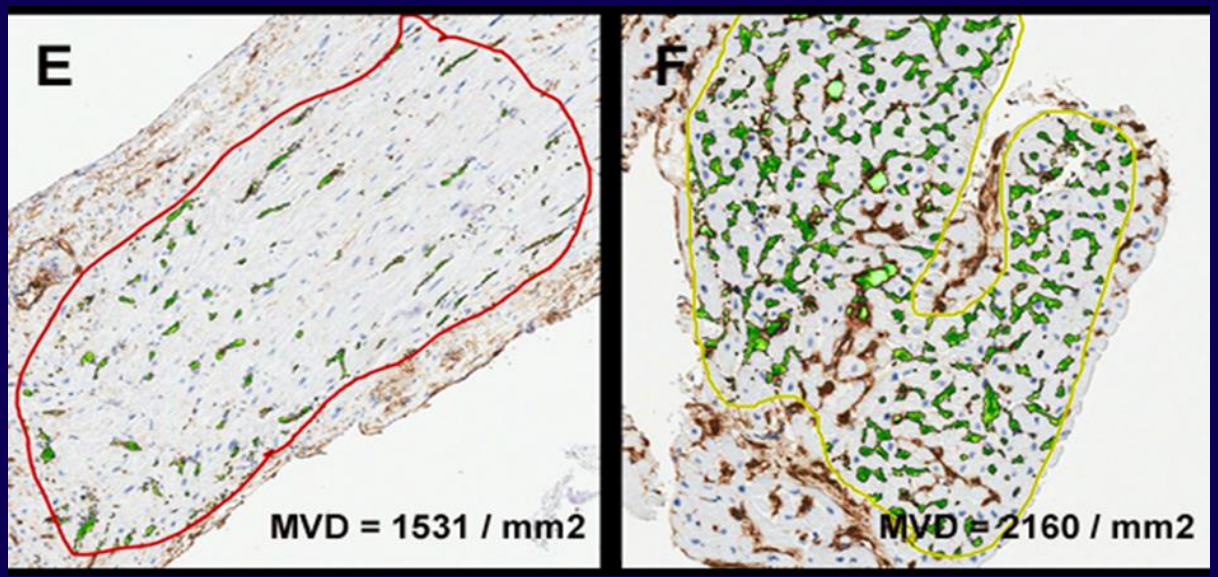

Structural changes in the microcirculation of EMB

Controversy about the existence and role of stenotic/thickening changes in arterioles and small arteries with pro [Hiemann *et al.* Circulation 2007] and contra [Armstrong *et al.* JHLT 1996];

Abu-Qaoud *et al.* [Transplantation 2012] found no relationship with CAV

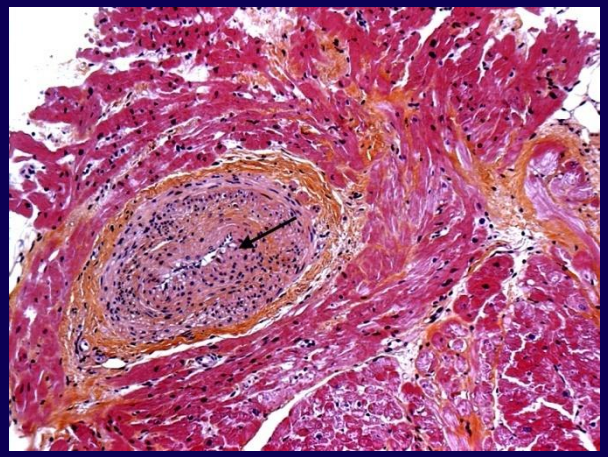

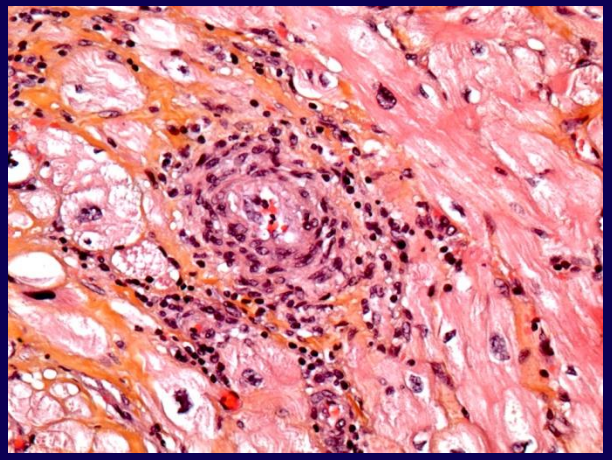

Chronic ABMR in cardiac transplantation

In summary:

- **CAV remains the paradigm of chronic ABMR, but with a complex pathophysiology including non-immune factors**
- **structural changes in the microcirculation need further investigations**

Conclusion

- Long term (on-going or fluctuating) humoral damage to the cardiac graft exists
- So far its expression is CAV
- The main reason to use “chronic ABMR” instead of CAV, would be that lesions other than CAV develop during immune damage to the graft: for ex. damage to the microcirculation
- We need to identify structural and/or molecular markers of chronic ABMR on EMB correlated with CAV development