Banff-SCT 2017
Towards Uniformity of Terminology for the Pathology of CAV

Gerald J. Berry, MD
Dept. of Pathology
Stanford University
Stanford, CA

Objectives

- Review current terminology
- Identify key histopathologic findings for development of classification of CAV
- Develop protocols for specimen handling, dissection, staining
- Develop criteria and terminology for CAV

Published Terms

- Coronary Allograft Vasculopathy (CAV)
- Cardiac Allograft Vasculopathy (CAV)
- Transplant Allograft Vasculopathy(TAV)
- Transplant Coronary Artery Disease (T-CAD)
- Graft Vascular Disease (GVD)
- Graft Coronary Disease (GCD)
- Transplant Vasculopathy (TV)
- Graft Coronary Vascular Disease (CVD)
- Chronic Rejection
- Accelerated Coronary Artery Disease
- Allograft Vasculopathy
- Allograft Arteriopathy
- Transplant Coronary Disease
- Cardiac Transplant Arteriosclerosis
- Accelerated Graft Arteriosclerosis
- *Transplant Atherosclerosis*
- *Accelerated Atherosclerosis*

Unresolved Issues

- CAV as epicardial disease +/- intramyocardial compartment
- Rarely the intramyocardial component predominates
- What about the vasovasorum, aorta, veins/venules and microvasculature?
- Should we consider 2 groups: 1. arteries to aorta +/- venous elements; 2. microvasculature including intramyocardial arteries and arterioles
- Can we recognize early versus late changes? Is there a morphologic spectrum?
- How do we approach mixed CAV and native ATS?
- Are pediatric and adult CAV lesions the same?

Unresolved Issues

- Do we focus exclusively on the intima?
- Is there a morphologic spectrum in intima?
- Is it temporal: early vs. late changes
- Are lipid-rich lesions part of CAV or ATS?
- How to handle mixed lesions? Which came 1st?
- Are there medial and adventitial lesions that are unique to CAV?

Aim of Classification

- Is the goal a descriptive set of categories alone?
- Is there a managerial or pathogenetic component? e.g., correlation with angiographic data, animal models, etc
- How do we incorporate macroscopic and microscopic findings?

ISHLT CONSENSUS STATEMENT

International Society for Heart and Lung Transplantation working formulation of a standardized nomenclature for cardiac allograft vasculopathy—2010

Mandeep R. Mehra, MD, Maria G. Crespo-Leiro, MD, Anne Dipchand, MD, Stephan M. Ensminger, MD, PhD, Nicola E. Hiemann, MD, Jon A. Kobashigawa, MD, Joren Madsen, MD, PhD, Jayan Parameshwar, MD, Randall C. Starling, MD, MPH, and Patricia A. Uber, BS, PharmD

From the ISHLT Working Group on Classification of Cardiac Allograft Vasculopathy commissioned by the Education Committee and Board of Directors of the Society

Mehra MR et al. *J Heart Lung Transplant* 2010; 29:717-27

Lipid-Rich CAV vs Fibrous-Rich CAV

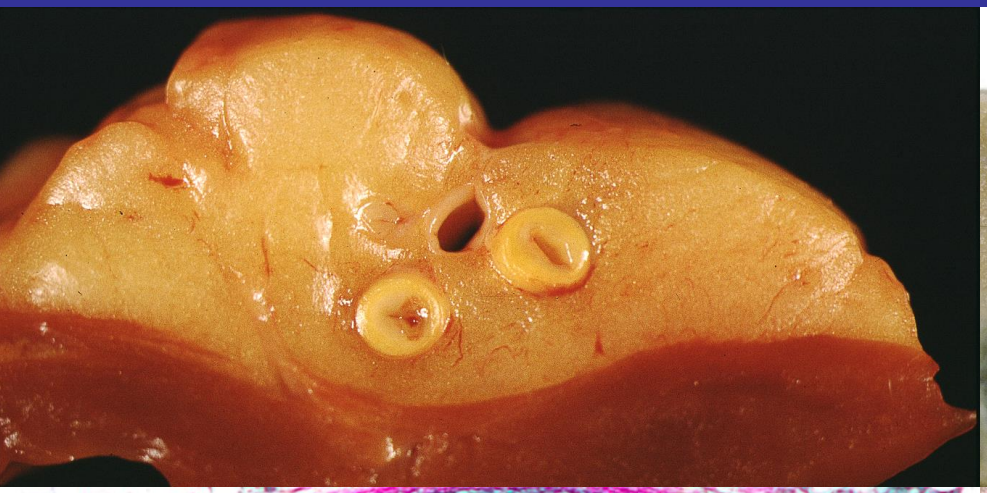

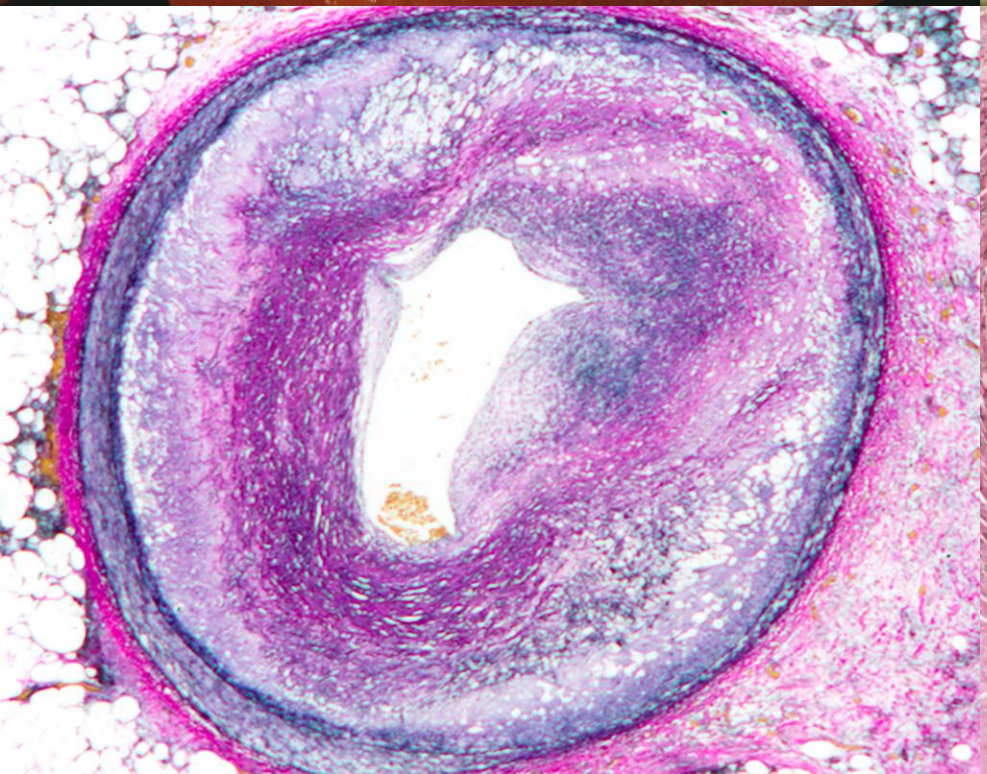

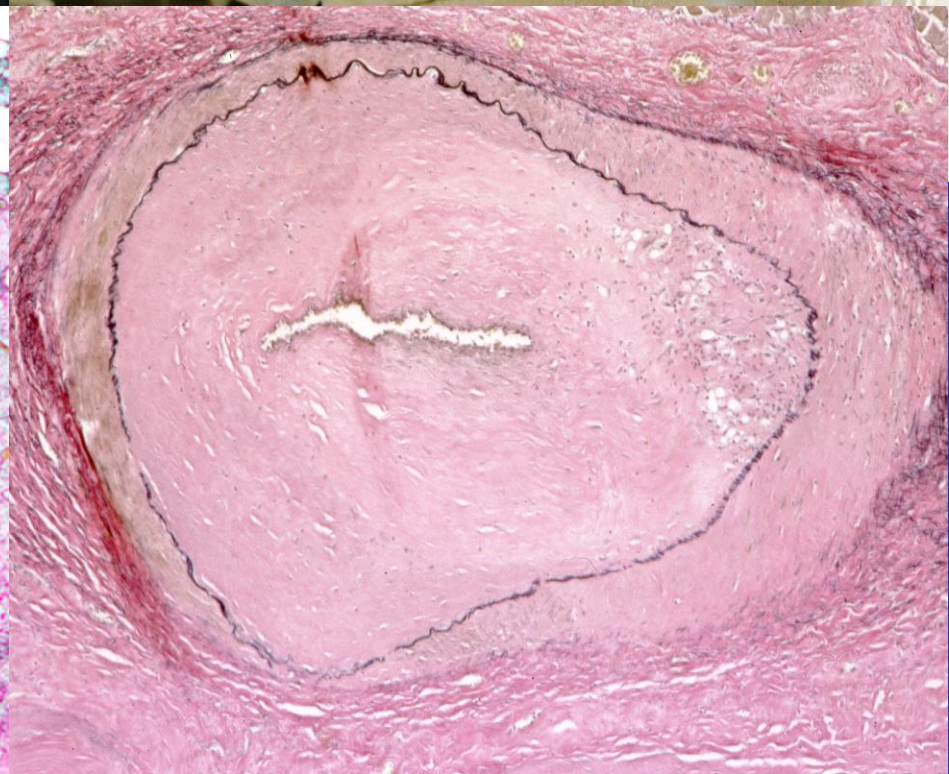

CAV vs AS

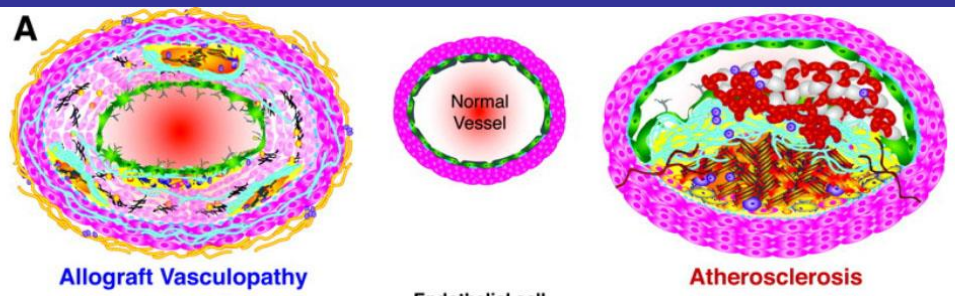

	Endothelial cell	
-/+	Denuding injury	+++
+++	Non-denuding injury	+++
+++	Hyper-permeability	++
+++	Dysfunction	++
	Smooth muscle cell	
++	Proliferation	+++
+++	Apoptosis	++
	ECM accumulation and function	
+++	Proteoglycan	+
++	Collagen (fibrosis)	+++
++	**Altered vascular myogenic tone in resistance vessels**	+
+++	**Adhesion molecule expression**	+++
	Inflammatory cells	
+	Platelets	+++
++	Monocytes/Macrophages	+++
+++	Lymphocytes	++
	Immune response	
+++	Innate/Acquired Immunity	++
+++	**Lipid retention**	++
	Risk factors	
++	High blood cholesterol	+++
+++	High blood triglycerides	+
+	Low blood HDL-C	+++
++	Hyperhomocysteinemia	+
-/+	Infection	-/+
-/+	Age	+++
-/+	Sex	++
-/+	Ethnicity	+
-/+	Established vascular disease	+
++	Smoking	+++
++	Diabetes mellitus	+++
++	Blood pressure elevation	++
++	Obesity	++
-/+	Sedentary life style	++
++	Special medications	+
-/+	Social class	+
-/+	Psychosocial environment	+
-/+	Type A behavior	-/+
+	Donor related disease	N/A
-	Family history	++

Maziar Rahmani et al. Circ Res. 2006;99:801-815

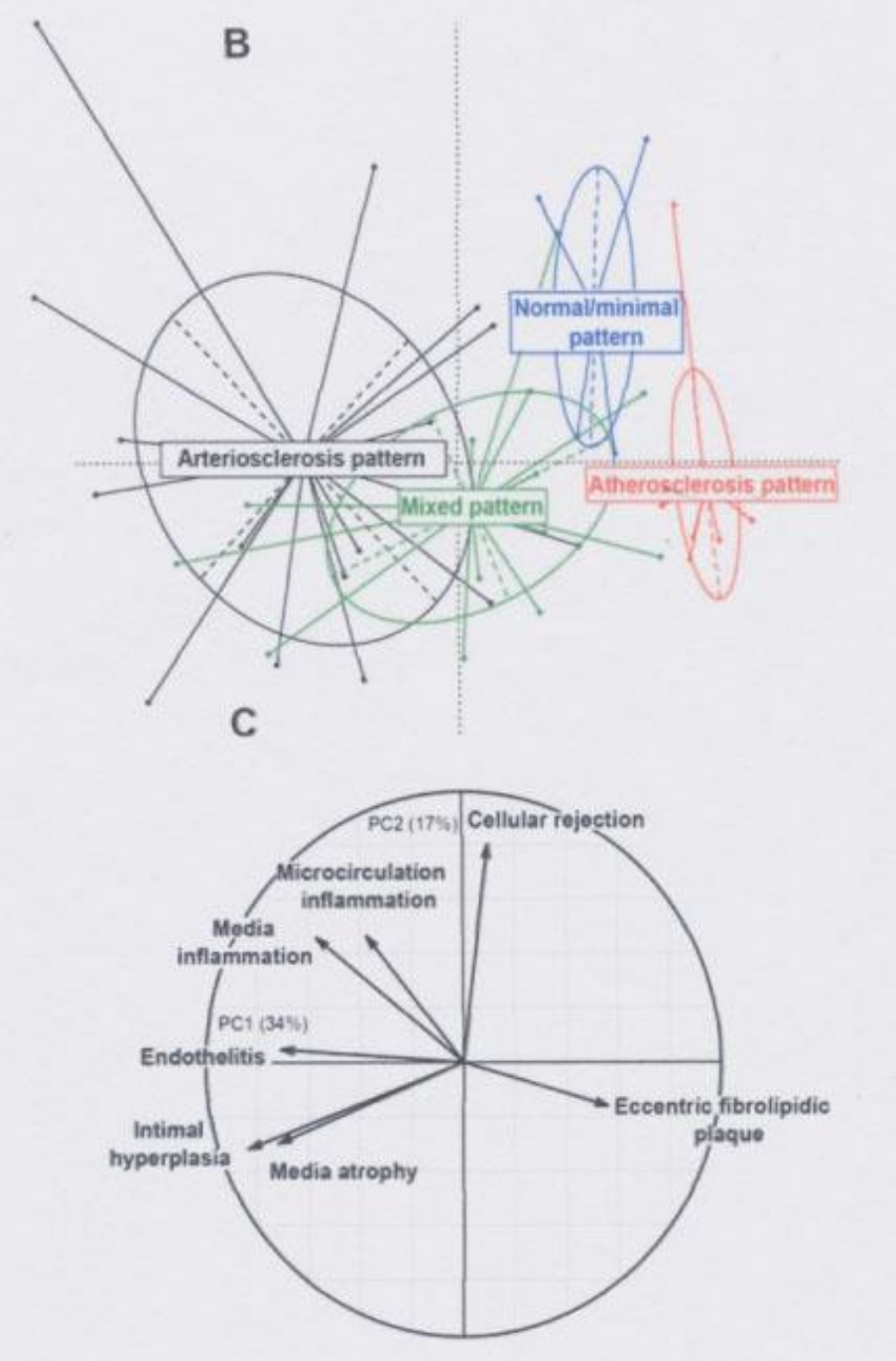

Loupy A ey al. AJT 2016; 16:111-120

Selected Published Studies

- Usy CJ and Rose AG. *Arch Pathol Lab Med* 1984; 108:112-116
- Pucci A et al. J Heart Transplant 1990; 9:339-45
- Johnson DE et al. *J Heart Transplant* 1989; 8:349-59
- Foerster A. APMIS 1992; 100:367-76
- Berry GJ et al. *J Heart Lung Transplant* 1993; 12:S309-S19
- Lu, W-h et al. *J Heart Lung Transplant* 2011; 30:1044-50
- Angelini A et al. *Virchows Arch* 2014; 464:627-35.
- Loupy A et al. *Am J Transplant* 2016; 16:111-20

The Spectrum of Coronary Artery Pathologic Findings in Human Cardiac Allografts

Danna E. Johnson, MD,* Shao Zhou Gao, MD,** John S. Schroeder, MD, FACC,** William M. DeCampli, MD, PhD,*** and Margaret E. Billingham, MB, BS, FACC****

Coronary artery morphologic features of 61 human cardiac allografts of short- and long-term survival were correlated with coexisting myocardial pathologic findings and cause of death. On the basis of distribution of coronary lesions, allografts were divided into two broad groups: those with fibrous or atherosclerotic lesions confined to the proximal region of epicardial arteries and those with diffuse necrotizing vasculitis or atherosclerosis of the entire coronary arterial system. Within the two groups, coronary artery morphologic features varied in a time-dependent fashion. Disease in the proximal region began as concentric fibrous intimal thickening, with atheromatous lesions observed after 1 year after transplantation. Five of 10 (50%) patients with atheromatous plaques in the proximal region of arteries died or underwent retransplantation because of coronary disease, as compared to only 1 of 29 (3%) patients with fibrous intimal thickening only in the proximal region. The earliest form of diffuse disease was a necrotizing vasculitis, which was invariably associated with acute myocardial rejection. Long-term survivors with diffuse disease showed severe fibrous or fibrofatty intimal lesions of the large and small epicardial and intramyocardial arteries. In some, diffuse disease may have resulted from healing of necrotizing vasculitis. Eight of nine (89%) long-term survivors with diffuse coronary artery disease died or required retransplantation because of coronary vascular disease. The coronary artery disease of human cardiac allografts is a heterogeneous phenomenon with variable distribution, morphologic features, severity, clinical significance, and, possibly, pathogenesis.
J Heart Transplant 1989;8:349-59.

Stanford Study 1989

- Luminal Narrowing: 0-25%, 26-50%, 51-75%; >75%
- Classification:
  - No Intimal Thickening
  - Fibrous Intimal Thickening of Proximal to Mid Epicardial arteries
  - Diffuse Necrotizing Vasculitis
  - Fibrofatty ATS plaques of Proximal to Mid epicardial arteries
  - Diffuse Fibrous Intimal Thickening +/- ATS plaques

Johnson DE et al. J Heart Transplant 1989; 8:349-59

Pathologic Features in Long-term Cardiac Allografts

Angela M. Pucci, MD,[a] R. D. Clarke Forbes, MD, FRCP(c),[b] and
Margaret E. Billingham, MB, BS, FRCPath, FCAP, FACC[c]

Pathologic conditions of six long-term orthotopic heart transplant survivors (11 to 17 years) was compared with a group of six similar heart transplant recipients surviving only 2 years. The two groups were matched as far as possible for age and sex of both recipients and donors and for immunosuppressive therapy (azathioprine and prednisone). Ischemic time, HLA-A, -B typing, acute rejection episodes, lipid profiles, and coronary angiograms were investigated in both groups. None of these parameters correlated with survival or disease of the graft. Graft coronary disease was present in 10 of 12 cases and caused graft failure in 8 of 12. All six long-surviving grafts and four of six surviving only 2 years showed occlusive coronary disease. The major difference in the two groups was in the pathologic condition of the coronary arteries in the long-term survivors, which more resembled that of naturally occurring atherosclerosis than the characteristic concentric graft coronary disease present in grafts surviving 2 years. Although the histopathologic features were different in the two groups, no investigated factor was useful in predicting graft disease and survival. J Heart Transplant 1990;9:339-45.

Graft Coronary Disease in Pediatric Heart and Combined Heart-lung Transplant Recipients: A Study of Fifteen Cases

Gerald J. Berry, MD,[a] Mona N. Rizeq, MD,[a] Lawrence M. Weiss, MD,[b] and Margaret E. Billingham, MB[a]

TABLE II Histopathologic findings in 15 cases

Group	Patient No.	Intimal proliferation (0-3)	Distribution of lesions	Inflammatory cells (0-3)	Internal elastic membrane	Vasculitis	Calcification (0-3)	Natural atherosclerosis	Cardiac rejection (ISHLT)
1 (0-5 yr)	659	3	Epi	3	D	Yes	0	0	NER
	625	3	Epi	1	I	No	0	0	NER
	667	3	Epi and intramyo	2	FD	Yes	0	0	1A
	2092	3	Epi	1	FD	No	0	0	1A
2 (6-14 yr)	492	2	Epi	1	I	No	0	0	3A
3 (15-18 yr)	368	3	Epi	1	I	No	0	0	NER
	271	2	Epi and atheroscl	0-1	FD	No	0	0	NER
	119	2	Epi and atheroscl	0-1	FD	No	3	2	1B
	216	3	Epi	1	FD	No	0	2	NER
	74 (1974)	3	Epi and intramyo	1	I	No	0	0	NER
	74 (1985)	2	Epi	3	FD	No	2	0	1A
	277	1	Epi and atheroscl	1	FD	No	2	0	1B
	2051	2	Epi and atheroscl	1	I	No	0	2	NER
	2057	2	Epi	1	FD	No	0	2	NER
	221	3	Epi and atheroscl	0-1	FD	No	0	2	NER

Epi, Major epicardial vessels and branches; *Intramyo,* intramyocardial branches; *Atheroscl,* superimposed atherosclerosis; *I,* intact; *D,* disrupted; *FD,* focal disruption; *0,* absent; *3,* marked/severe.

Berry GJ et al. J Heart Lung Transplant 1993; 12:S309-S19

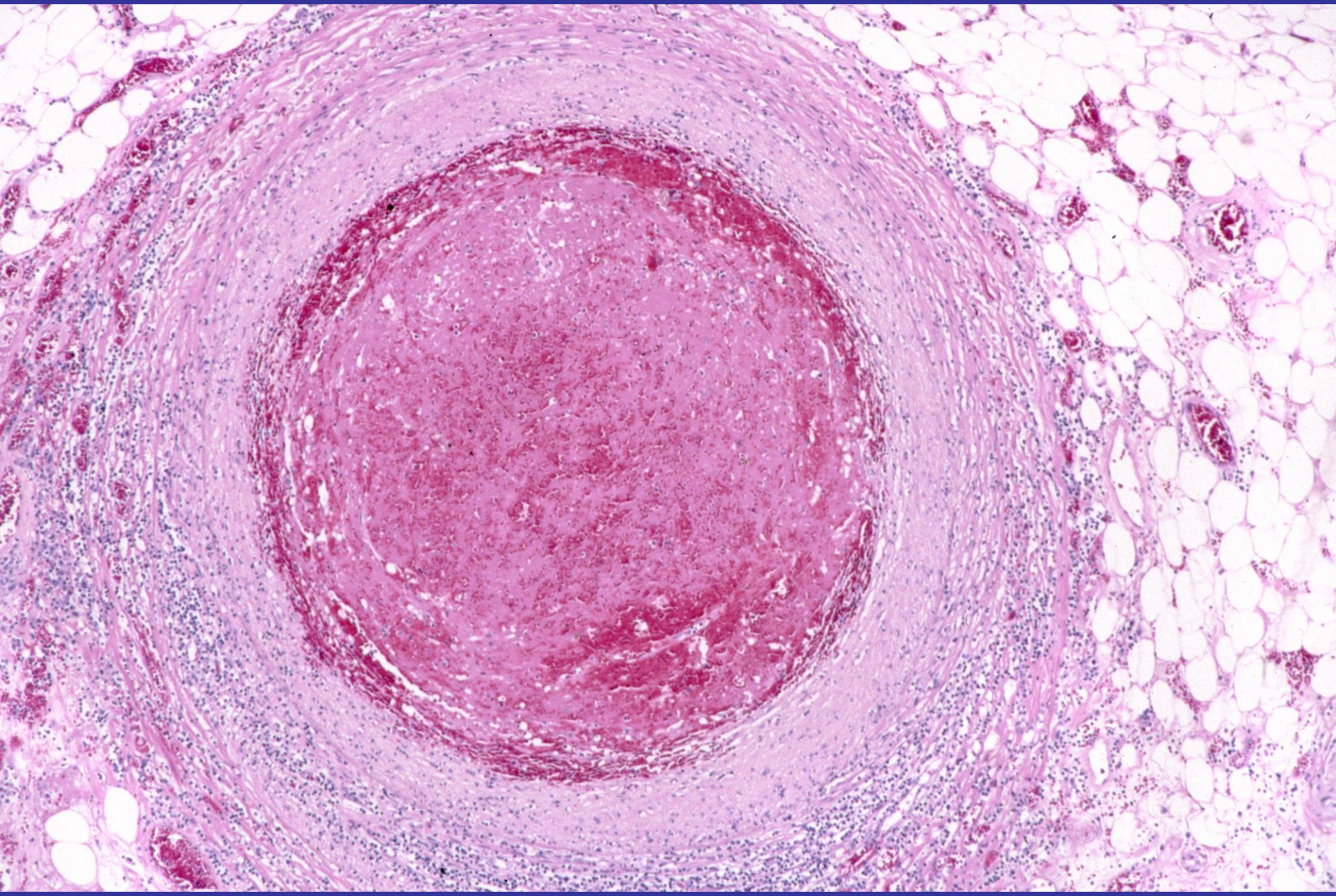

Diverse morphologic manifestations of cardiac allograft vasculopathy: A pathologic study of 64 allograft hearts

Wei-hui Lu, MD,[a] Kathy Palatnik, BS,[a] Gregory A. Fishbein, BA,[a] Chi Lai, MD, FRCPC,[a] Daniel S. Levi, MD,[b] Gregory Perens, MD,[b] Juan Alejos, MD,[b] Jon Kobashigawa, MD,[c] and Michael C. Fishbein, MD[a]

BACKGROUND: Cardiac allograft vasculopathy (CAV) is a major limitation to the long-term success of cardiac transplantation. Although there are published descriptions of the lesions, there have been no studies delineating the pathology of CAV in a large series of patients who underwent retransplantation for CAV.

METHODS: We reviewed archival records and microscopic sections of surgically explanted hearts from 64 patients who underwent cardiac retransplantation: 54 adults (18 to 70 years old) and 10 children (3 to 15 years old). Vascular lesions were categorized as showing intimal fibromuscular hyperplasia, atherosclerosis and/or inflammation. The degree of luminal narrowing was estimated from gross descriptions and microscopic sections.

RESULTS: In total, 75% of hearts had evidence of acute cellular rejection, mostly mild. Intramyocardial arteries showed primarily intimal fibromuscular hyperplasia and inflammation with no atheromas present. Large and branch epicardial coronary arteries were narrowed in at least one artery of all hearts. Lesions in the epicardial coronary arteries were composed of intimal fibromuscular hyperplasia, atherosclerosis and/or inflammation affecting one or more vascular layers (intima, media and adventitia). Severe CAV with >75% luminal narrowing was seen in the LAD in 17% of hearts, the LCx in 17% and the RCA in 22% of hearts. Two hearts had severe narrowing of the left main coronary artery. Nineteen arteries had luminal thrombi. All hearts had narrowing of smaller epicardial branch coronary arteries that was often severe. Atheromas were present in arteries of adults and children; thus, not all atheromas could be considered pre-existing prior to transplantation. Both arteries and veins showed intimal hyperplasia and inflammation.

CONCLUSIONS: CAV is a pathologically multifaceted disorder that affects large and small epicardial coronary arteries of adults and children, with different types of lesions: intimal fibromuscular hyperplasia; atherosclerosis; and/or inflammation (vasculitis). Therapies to address this disease must take into account the protean nature of the vascular lesions.

J Heart Lung Transplant 2011;30:1044–50

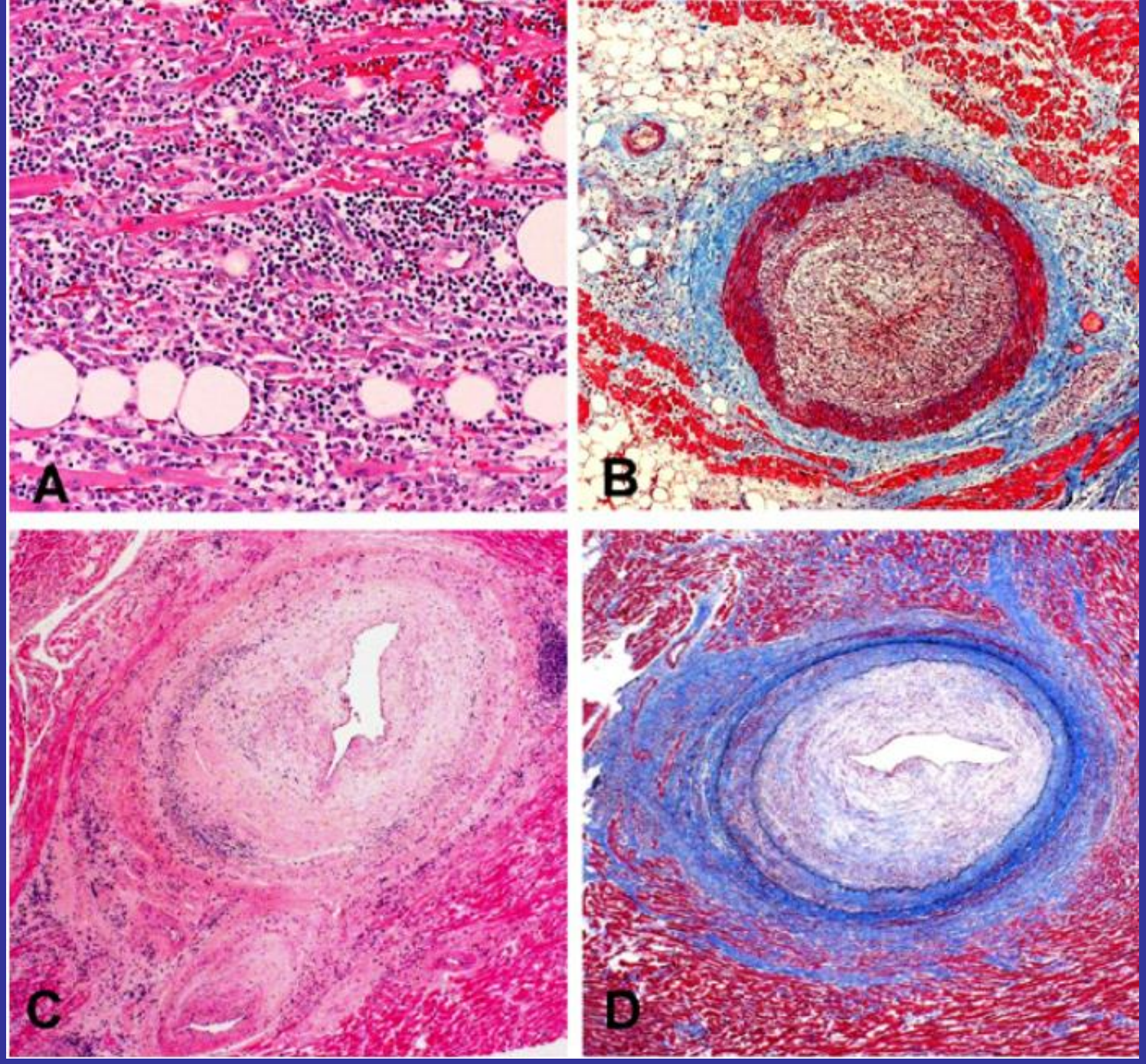

Lu W-h et al. J Heart Lung Transplant 2011; 30:1044-50

Coronary cardiac allograft vasculopathy versus native atherosclerosis: difficulties in classification

Annalisa Angelini · Chiara Castellani · Marny Fedrigo · Onno J. de Boer · Lorine B. Meijer-Jorna · Xiaofei Li · Marialuisa Valente · Gaetano Thiene · Allard C. van der Wal

Angelini A et al. Virchows Arch 2014; 464:627-635

Table 2 Key points

Key points
CAV lesions are more inflamed than ATS with more microvessels and leakage
IPH is a morphological features of CAV lesions and of FC plaques and act as atherogenic stimulus
IPH is associated with the presence of microvessels and inflammation
Adventitia is reflecting the plaque characteristics in terms of inflammation and microvessels
Adventitia is characterized by fibrous remodeling more deeply in CAV than in ATS
Early lesions are more inflamed than late lesions
Inflammatory cells types differs in CAV vs ATS
CD68 macrophages positive cells are less pronounced in CAV than ATS lesions
Correlations between the various pathological substrates of CAV and in vivo coronary artery imaging (virtual histology) need to be further worked out systematically

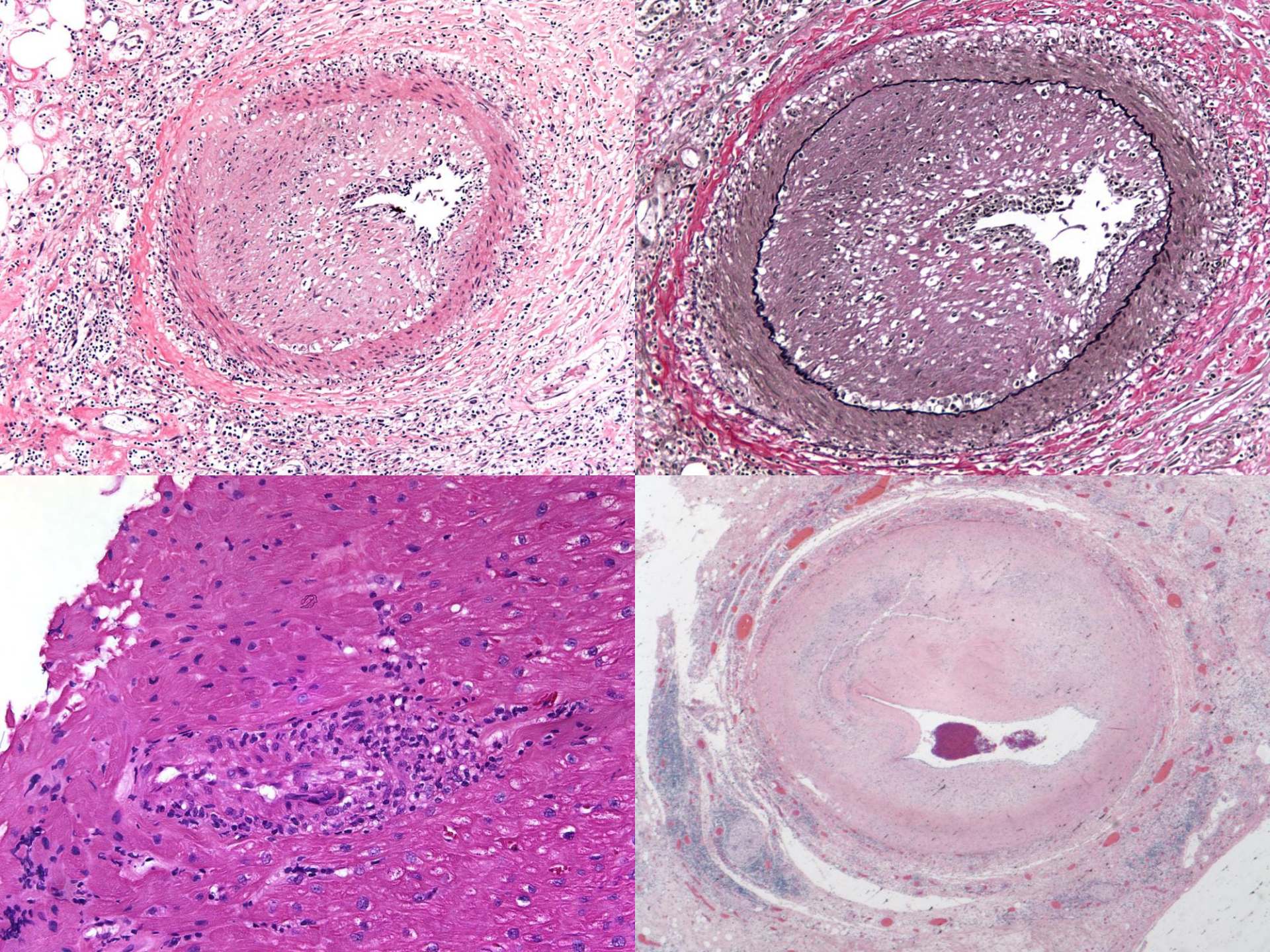

Atherosclerotic (ATS) Lesions

Terms for Atherosclerotic Lesions in Histological Classification		Other Terms for the Same Lesions Often Based on Appearance to the Unaided Eye	
Type I lesion	Initial lesion	Fatty dot or streak	Early lesion
Type II lesion			
IIa	Progression-prone type II lesion		
IIb	Progression-resistant type II lesion		
Type III lesion	Intermediate lesion (preatheroma)		
Type IV lesion	Atheroma	Atheromatous plaque, fibrolipid plaque, fibrousplaque, plaque	Advanced lesions, raised lesions
Va	Fibroatheroma (type V lesion)		
Vb	Calcific lesion (type VII lesion)	Calcified plaque	
Vc	Fibrotic lesion (type VIII)	Fibrous plaque	
Type VI lesion	Lesion with surface defect and/or hematoma/hemorrhage and/or thrombotic deposit	Complicated lesion, complicated plaque	

	Description	Thrombosis
Nonatherosclerotic intimal lesions		
Intimal thickening	The normal accumulation of smooth muscle cells (SMCs) in the intima in the absence of lipid or macrophage foam cells	Absent
Intimal xanthoma, or "fatty streak"	Luminal accumulation of foam cells without a necrotic core or fibrous cap. Based on animal and human data, such lesions usually regress.	Absent
Progressive atherosclerotic lesions		
Pathological intimal thickening	SMCs in a proteoglycan-rich matrix with areas of extracellular lipid accumulation without necrosis	Absent
Erosion	Luminal thrombosis; plaque same as above	Thrombus mostly mural and infrequently occlusive
Fibrous cap atheroma	Well-formed necrotic core with an overlying fibrous cap	Absent
Erosion	Luminal thrombosis; plaque same as above; no communication of thrombus with necrotic core	Thrombus mostly mural and infrequently occlusive
Thin fibrous cap atheroma	A thin fibrous cap infiltrated by macrophages and lymphocytes with rare SMCs and an underlying necrotic core	Absent; may contain intraplaque hemorrhage/fibrin
Plaque rupture	Fibroatheroma with cap disruption; luminal thrombus communicates with the underlying necrotic core	Thrombus usually occlusive
Calcified nodule	Eruptive nodular calcification with underlying fibrocalcific plaque	Thrombus usually nonocclusive
Fibrocalcific plaque	Collagen-rich plaque with significant stenosis usually contains large areas of calcification with few inflammatory cells; a necrotic core may be present.	Absent

Adventitial Lesions in CAV

- Nodular ("Epicardial Quilty lesions") vs diffuse inflammatory infiltrates
- Inflammatory and fibroproliferative changes in the vasovasorum
- Role in remodeling and pathogenesis of CAV is largely unknown
- Huibers MMH et al. Am J Transplant 2017; 17:246-54. "Ectopic Lymphoid Structures"

Points for Discussion

- Solitary term for allograft lesion
- Protocol for handling re-transplant and post mortem specimens
- Components of a classification

Cardiac Allograft Vasculopathy

- A. Fibrocellular Proliferative Type
  - Inflammatory Cell Rich: +/- plaque disruption/thrombosis
    - Lymphocyte Predominant
    - Lipid cell Predominant
  - Inflammatory Cell Poor: +/- plaque disruption/thrombosis
  - Fibrotic: +/- plaque disruption/thrombosis
- B. Vasculitic Type
  - Epicardial Arteries and Branches
  - Intramyocardial Arteries
- C. Atherosclerotic (ATS) Type (AHA or other classifications)
- D. Mixed Fibrocellular Proliferative-Atherosclerotic Type
  - Fibrocellular Proliferative Predominant
  - Atherosclerotic Predominant
- E. Adventitial-Rich Lesions
  - Inflammatory Cell Rich: Diffuse versus Nodular
  - Inflammatory Cell Poor